

Conservative treatment of a cervical twin pregnancy with uterine artery embolization

Leila Ben Farhat, Yosr Ben Salah, Anis Askri, Nadida Dali, Lotfi Hendaoui

ABSTRACT

Cervical pregnancy is a rare form of ectopic pregnancy. Its treatment has been described by different authors. We report our successful experience of a cervical twin pregnancy that was diagnosed by transabdominal and transvaginal ultrasound and confirmed by magnetic resonance imaging. To preserve fertility, our patient was treated by a bilateral hyperselective uterine artery embolization followed by dilatation and curettage of the cervical canal without ancillary procedures for cervical hemostasis. Arterial embolization by a resorbable agent reduces arterial circulation by providing a temporary occlusion of the vessels in order to decrease the risk of massive hemorrhage.

Key words: • pregnancy, ectopic • cervix uteri • ultrasonography • uterine artery embolization

Cervical pregnancy is a rare form of ectopic pregnancy, which accounts for about 0.1% of such pregnancies (1). The diagnosis of cervical pregnancy is difficult and commonly delayed. It is made in the majority of cases in the presence of massive blood loss, necessitating an emergency hysterectomy in about 50% of cases (2). Cervical pregnancy has a high morbidity potential because of hemorrhage. However, mortality has decreased because of early ultrasonographic diagnosis and new treatment options to prevent life-threatening bleeding.

In this report, we present our successful experience with preoperative embolization of the uterine artery.

Case report

A 41-year-old gravida 2 para 1 woman presented to the emergency department with amenorrhea for 11 weeks and painless vaginal spotting for 2 days. She was treated for threatened abortion by a progestative agent. Her obstetrical history was significant for a lower-segment cesarean section because of severe preeclampsia. She had no previous intrauterine procedures, pelvic inflammatory disease, or intrauterine devices. Her medical and surgical history were otherwise unremarkable.

Four days after her initial visit, she presented to our obstetrical emergency service for persistence of painless vaginal spotting and dizziness. Clinical examination showed stable vital signs, and her abdomen was soft and nontender. Gynecological examination revealed a slightly enlarged uterus without adnexal masses. Vaginal examination revealed an anterior position of the cervix, which was extremely thin, with the external os closed; speculum examination showed a small amount of cervical bleeding. Hemoglobin was 12 g/dL and hematocrit was 34.2%.

Transabdominal and transvaginal ultrasound (US) examinations confirmed the presence of a cervical twin pregnancy with two gestational sacs. One sac contained a live fetus with a 40 mm crown-rump length (CRL); the other contained a fetus with a CRL of 31 mm and no cardiac activity. Magnetic resonance imaging (MRI) was performed to improve diagnostic accuracy. It confirmed the cervical implantation of two gestational sacs and showed a fine cervical myometrium (Fig. 1).

To preserve fertility, conservative treatment was proposed to the patient. Treatment was initiated by intraamniotic injection of potassium chloride guided by US to stop fetal heartbeat. Cardiac activity stopped immediately after injection. The following day, the patient underwent percutaneous catheterization of the femoral artery (5 F catheter) under local anesthesia. The selective uterine artery angiograms showed that the embryonic vessels were filled predominantly from the left side uterine artery (Fig. 2). We started by embolizing left uterine artery. Embolization was performed with resorbable particles mixed with diluted contrast material. This mixture was injected until the uterine arterial flow

From the Department of Radiology (L.B.F. ✉ leila.benfarhat@rns.tn), Mongi Slim Hospital, La Marsa, Tunisia.

Received 8 July 2008; revision requested 25 August 2008; revision received 26 August 2008; accepted 30 August 2008.

Published online 19 October 2009
DOI 10.4261/1305-3825.DIR.2073-08.1

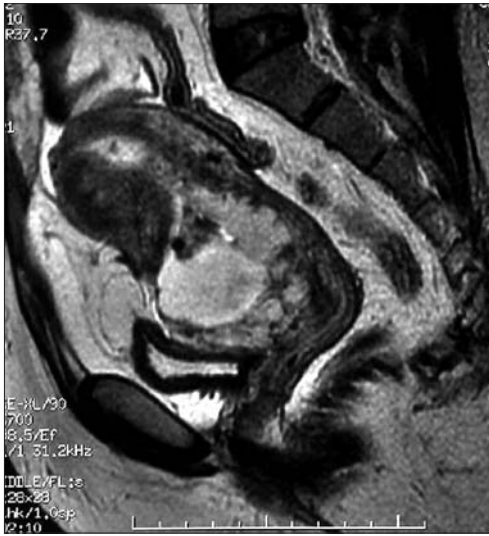

Figure 1. Sagittal T2-weighted MR image shows a heterogenous high-signal intensity mass that occupies the cervical anterior wall, which is very fine.

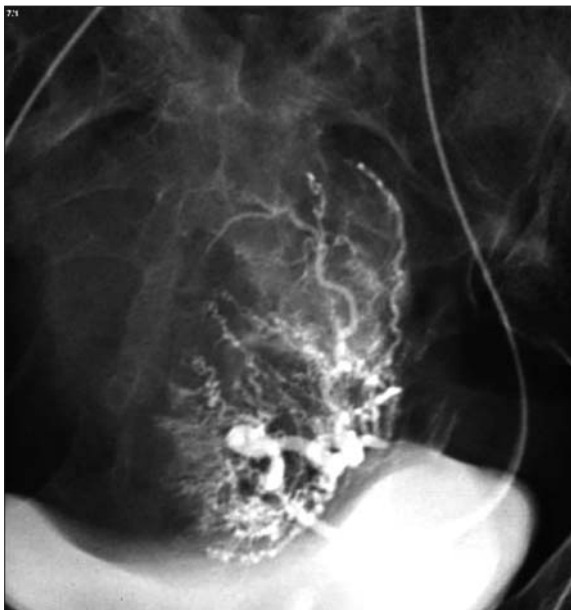


Figure 2. Arteriogram of the left uterine artery before embolization showing a hypertrophied and tortuous uterine artery. The vascularity is seen at the lower uterine segment and cervix.

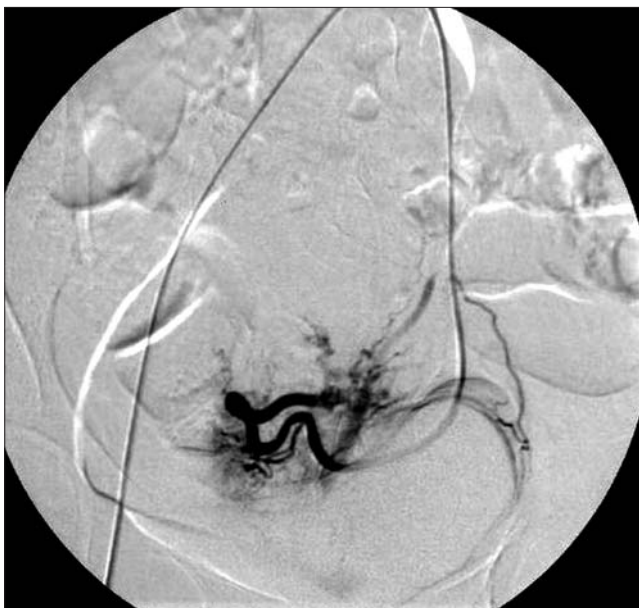

Figure 3. Arteriogram of the left uterine artery after embolization. Only collateral vascularization is seen.

ceased (Fig. 3). Right uterine artery embolization was performed in the same fashion. During this embolization, analgesics were administered to prevent pelvic pain. Two days after the embolization, curettage of the cervical canal was done with an estimated blood loss of 100 mL.

Two days after the curettage, an US exam showed a normal uterine cervix, and the patient was discharged.

Discussion

Cervical ectopic pregnancy is a rare and serious form of ectopic pregnancy (2). It is characterized by abnormal implantation of a fertilized ovum in the endocervical canal below the level of the internal os.

There are many predisposing factors for cervical pregnancy, such as intrauterine procedures, intrauterine insemination, in vitro fertilization (3), pelvic inflammatory disease, leiomyoma, intrauterine devices, and primary embryo anomaly; however, the cause of cervical pregnancy remains unknown (4).

Diagnosis of cervical ectopic pregnancy is based on clinical and US findings. The main US criteria, cited by Ruano et al. (4), are gestational sac in the cervix, empty uterine cavity, dilated cervix, and normal uterine size (excluding the alternative possibility of spontaneous abortion in progress). Transabdominal and transvaginal sonographic examinations allow for a diagnosis that is easy and fast, two important characteristics in such a serious disease.

In the present case transabdominal US showed a cervical single gestational sac with cardiac activity. Transvaginal US after maternal bladder was emptied confirmed the cervical position of a two gestational sacs, separated from the body of the uterus by a constrictive isthmus. Transvaginal US improves diagnostic accuracy in early detection of cervical pregnancy (4).

MRI has been used in few cases of cervical pregnancy. It is performed when the diagnosis by US is difficult (5). First, it is not usually available under emergency conditions; and second, it does not add important information to ultrasound findings. In our case the pregnancy was very precious and MRI was used to improve diagnostic accuracy.

There are two ways to treat cervical pregnancy; the conservative one when the fertility is still desired, and the non conservative one, which may be disastrous for young women. The conservative treatment is preferred to hysterectomy by most authors (2, 3, 6–9).

The most effective conservative treatment of cervical pregnancy is still under investigation. All forms of treatment have the common goal of minimizing the risk of life-threatening persistent bleeding and a dramatic hysterectomy.

In most cases reported in the literature conservative treatment includes a combination of both medical and surgical methods. Medical methods consist of intraamniotic or systemic injection of various chemotherapeutic agents. An US guided injection of 3–5 mL (6–10 mEq) of potassium chloride into the fetus or gestational sac was sufficient in four cases reported by Frates et al. (3); this method was used in our case to stop fetal cardiac activity. Yitzhak et al. reported that injection of methotrexate (0.5–1 mg/kg) associated with folinic acid was safe and simple (2). Methotrexate can be administered via the intraamniotic route (10). Feticide by direct puncture may lead to hemorrhagic incomplete abortion. The efficiency of methotrexate is limited and depends on advanced gestational age, high β -HCG level ($>50,000$ U/mL), and the presence of fetal cardiac activity (11). In our case the gestational age was considered advanced.

Methods for controlling bleeding include cervical cerclage, tamponade of the uterine cervix with a Foley catheter, local hemostatic sutures, curettage followed by local prostaglandin instillation (12), and vaginal packing; however, these procedures are usually not sufficient to stop hemorrhage. Other methods used include ligation of the descending branches of the uterine arteries, bilateral hypogastric artery ligation, or, as a last resort, hemostasis hysterectomy.

A prophylactic intraoperative transvaginal ligation of cervical branches of the uterine arteries was performed by Frates et al. (3). Combined treatment with temporary intraoperative balloon occlusion of the common iliac arteries and hysteroscopic endocervical resection for cervical pregnancy was reported to preserve fertility by Yang et al. (13).

Selective uterine arterial embolization is now accepted as a highly effective technique for controlling acute and chronic genital bleeding. It is considered as a safe and simple procedure with only transient complications. Uterine artery embolization is usually indicated to treat postpartum hemorrhage (14) and as an alternative to hysterectomy or myomectomy for women with symptomatic uterine fibroids (15). In cervical pregnancy, a successful association of selective uterine artery embolization with surgical and pharmacological treatment is used by most authors (7–9). Ryu et al. (6) performed preoperative embolization of the uterine artery before curettage without injection of any chemotherapeutic agent. Nadisauskiene et al. (7) performed systemic methotrexate injection, preoperative unilateral embolization of the uterine artery and curettage, followed by cervical balloon compression. Yitzhak et al. (2) performed injection of methotrexate and a bilateral uterine artery embolization, followed by curettage.

Artery embolization by resorbable particles reduces arterial circulation by occluding the vessels for 2–6 weeks (6). This procedure has many complications, including pelvic infection, pelvic pain, ischemia of tissues, and complications from angiography (1, 6). However, it is now the method of choice when treatment with methotrexate is too late or fails. Pelvic artery embolization reduces the risks inherent to the surgical procedure, avoids massive bleeding during or after the curettage, and reduces time of hospitalization (1, 6, 8, 9).

In conclusion, cervical pregnancy is a rare and serious form of ectopic pregnancy. Uterine artery embolization combined with chemotherapeutic agents is effective in the treatment of cervical pregnancy and has the advantage of preserving the woman's fertility.

References

1. Heikinheimo O, Leminen A, Cacciatori B, Rutanen EM, Kajanoja P. Advanced cervical pregnancy: uterus-sparing therapy initiated with a combination of methotrexate and mifepristone followed by evacuation and local hemostatic measures. *Acta Obstet Gynecol Scand* 2004; 83:211–213.

2. Yitzhak M, Orvieto R, Nitke S, Neuman-Levin M, Ben-Rafael Z, Schoenfeld A. Cervical pregnancy—a conservative stepwise approach. *Hum Reprod* 1999; 14:847–849.
3. Frates MC, Benson CB, Doubilet PM, et al. Cervical ectopic pregnancy: results of conservative treatment. *Radiology* 1994; 191:773–775.
4. Ruano R, Reya F, Picone O, et al. Three-dimensional ultrasonographic diagnosis of a cervical pregnancy. *Clinics (Sao Paulo)* 2006; 61:355–358.
5. Jung SE, Byun JY, Lee JM, Choi BG, Hahn ST. Characteristic MR findings of cervical pregnancy. *J Magn Reson Imaging* 2001; 13:918–922.
6. Ryu KY, Kim SR, Cho SH, Song SY. Preoperative uterine artery embolization and evacuation in the management of cervical pregnancy: report of two cases. *J Korean Med Sci* 2001; 16:801–804.
7. Nadisauskiene R, Vaickevicius E, Taraseviciene V, Simanaviciute D. Conservative treatment of cervical pregnancy with selective unilateral uterine artery embolization. *Medicina (Kaunas)* 2007; 43:883–886.
8. Martinelli P, Maruotti GM, Oppedisano R, et al. Is uterine artery embolization for cervical ectopic pregnancy always safe? *J Minim Invasive Gynecol* 2007; 14:758–763.
9. Trambert JJ, Einstein MH, Banks E, Frost A, Goldberg GL. Uterine artery embolization in the management of vaginal bleeding from cervical pregnancy: a case series. *J Reprod Med* 2005; 50:844–850.
10. Miyamura T, Masuzaki H, Ishimaru T. Conservative treatment of a cervical pregnancy with local methotrexate injection. *Int J Gynaecol Obstet* 1994; 45:62–63.
11. Kaplan BR, Brandt T, Javaheri G, Scommegna A. Successful treatment of a live cervical pregnancy with methotrexate and folinic acid. A case report. *J Reprod Med* 1989; 34:853–856.
12. Spitzer D, Steiner H, Graf A, Zajc M, Staudach A. Conservative treatment of cervical pregnancy by curettage and local prostaglandin injection. *Hum Reprod* 1997; 12:860–866.
13. Yang JH, Shih JC, Liu KL, Yang YS. Combined treatment with temporary intraoperative balloon occlusion of common iliac arteries and hysteroscopic endocervical resection with postoperative cervical balloon for intractable cervical pregnancy in an infertile woman. *Fertil Steril* 2007; 88:1438.e11–13.
14. Ojala K, Perälä J, Kariniemi J, Ranta P, Raudaskoski T, Tekay A. Arterial embolization and prophylactic catheterization for the treatment for severe obstetric hemorrhage. *Acta Obstet Gynecol Scand* 2005; 84:1075–1080.
15. Pinto I, Chimento P, Romo A, et al. Uterine fibroids: uterine artery embolization versus abdominal hysterectomy for treatment—a prospective, randomized, and controlled clinical trial. *Radiology* 2003; 226:425–431.